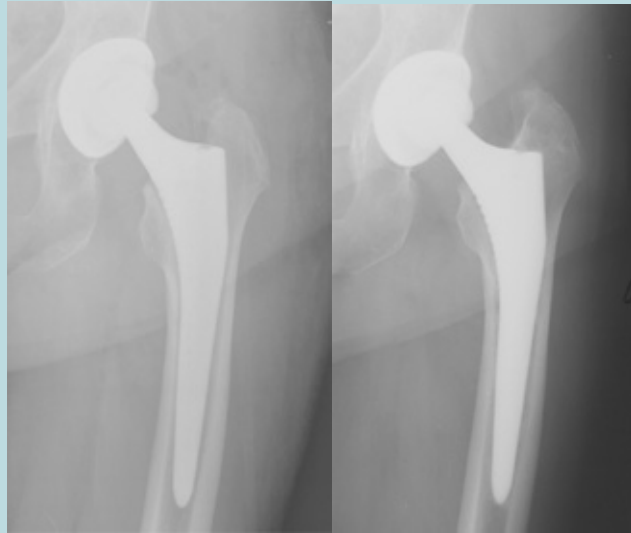
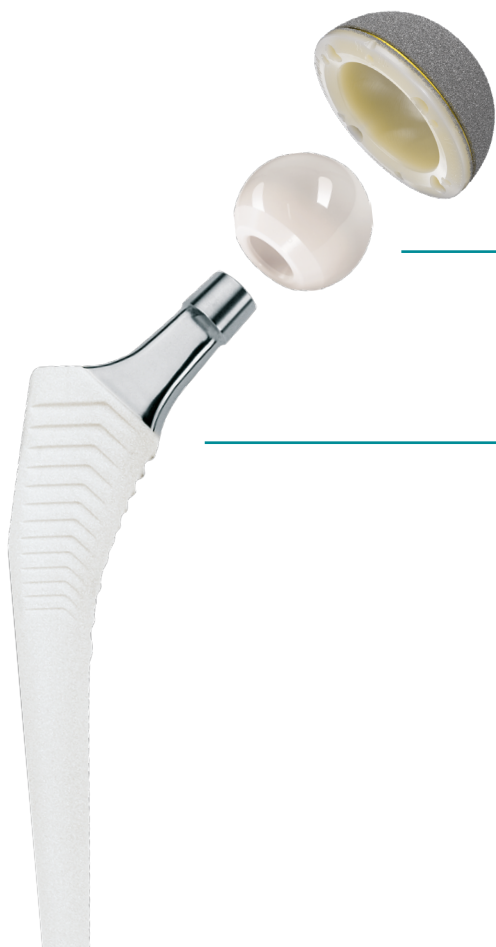

On register at national health surveillance agency



Example radiographs from a 77-year-old female patient taken: (a) postoperatively; and (b) at 5 years; (The subsidence level was 5.5 mm at 2 years).



RM Pressfit vitamys

Uncemented, elastic acetabular cup with monoblock design, made of low-abrasion plastic material ¹ (vitamin-E-stabilised highly cross-linked polyethylene)

Ceramic head

Femoral head that moves very easily and with low friction in the acetabular cup due to its highly polished surface ¹

TwinSys

Uncemented straight stem made of titanium, coated with hydroxyapatite to allow bone ongrowth on the prosthesis and anchoring in the bone ¹

Further information on implants can be found at:
www.my-artificial-joint.com

Reference

¹ www.mathysmedical.com/en/products/hip.html